



Utilization of Brazilian Spinach (*Alternanthera sissoo*) Leaf Extract as a Burn Medicine in Mice (*Mus musculus L.*)

Anugraheni Aditia Widyadhana¹, Amelia Putri Kinanthi², Natali Allya Graciandi Aryasa²,
Kukuh Madyaningrana^{*2,3}

¹SMA Negeri 11 Yogyakarta, Yogyakarta, Indonesia.

²Faculty of Biotechnology, Universitas Kristen Duta Wacana, Yogyakarta, Indonesia

³Yayasan Aliansi Ciawan Indonesia Thailand, Semarang, Indonesia.

- Corresponding: kukuh.madyaningrana@gmail.com

The author's address for correspondence is written in full including telephone number, postal code, and email.

Accepted: 24-03-2025 - Approved: 31-05-2025

ABSTRACT

Brazilian spinach (*Alternanthera sissoo* hort) leaves contained phytochemical compounds that offer a natural alternative to commercial burn treatments be. This study aimed to evaluate the burn-healing potential of Brazilian spinach leaf extract formulated into an ointment. The leaves were extracted using maceration with 96% ethanol. Phytochemical screening revealed the presence of alkaloids, flavonoids, tannins, saponins, steroids, and vitamin E. The ethanol extract was incorporated into ointments at concentrations of 2%, 4%, and 8%. An in vivo study was conducted using 20 BALB/C mice divided into five groups: negative control (KN), positive control (KP), and three treatment groups (P1: 2%, P2: 4%, P3: 8% extract ointment). Burn injuries were induced by applying heated metal to the shaved dorsal region of the mice. Treatments were applied daily for 7 days. Healing progress was assessed based on burn severity score and burn surface area. Results demonstrated a significant reduction in both parameters across all treatment groups, with the 4% extract ointment (P2) showing the most optimal healing effect. These findings suggest that Brazilian spinach leaf extract, particularly at a 4% concentration, has promising potential as a natural topical agent for burn treatment

Key words: *Alternanthera sissoo* hort , leaves extract, Mice, Burn, Surface Area Scoring

INTRODUCTION

Burn, also known as *combustio* or *burn*, are a form of trauma that occurs to the skin, mucosa, or deeper tissues in the body caused by direct contact with heat sources, high voltage electrical sources and currents, radiation, and certain chemical compounds (Rahayuningsih, 2012; Arif, 2017). Burn can be categorized as a common type of injury. Burn on the body can lead to decreased metabolic processes in the body and disrupt the cardiovascular system (Rahayuningsih, 2012). Based on data from the *World Health Organization* (WHO) in Hasanah *et al.* (2023), as many as 180,000 burn victims die from a total of 11 million burn cases per year, so burn have a

high risk of death. Based on data from the *American Burn Association* in Thedjakusuma (2022) from 2011-2015, the total number of burn patients treated per year was 486,000 people. Furthermore, burn in Indonesia itself have a prevalence of 0.7%, according to Basic Health Research (RISKESDAS) data.

The extent and depth of the burn needs to be considered, when performing burn management. The depth of a burn is influenced by the caloric content of the wound medium, duration of exposure, and temperature. In addition, the severity of the burn also needs to be observed, which is caused by several things including: the part of the body exposed, the area of the body exposed, the intensity of the caloric energy, and the exposure time between the body part and the trigger source, as well as other complicating factors (Syaiful *et al.*, 2023). In terms of severity, burn can be categorized into four categories, namely: First degree burn, superficial second degree burn, deep second degree burn, and third degree burn (Rahayuningsih, 2012). According to Saputra (2023), burn that occur can be categorized according to their cause, including: *flame burn*, *contact burn*, hot liquid burn, *scald burn*, occupational burn, *chemical burn*, lightning burn, electrical burn, fireworks burn, and accidental burn.

Skin burn can lead to pathophysiological changes. This depends on the extent of the burn area and the size of the burn. When the burn is small, a local response occurs, while when the burn is large enough, a systemic response occurs (Rahayuningsih, 2012). In 1st degree burn, pathophysiological symptoms include: disruption of the outermost layer of the epidermis, redness of the skin (*erythema*), slight pain and swelling (*edema*). In 2nd degree burn, the pathophysiological symptoms include severe pain, edema, and the altered skin includes the epidermis and dermis. Finally, in third-degree burn, pathophysiological symptoms include: disruption of all layers of the skin and can reach the tissue inside (Hasanah *et al.*, 2023).

The research of Wuni et al. (2022) showed that Brazilian spinach leaves have a dominant content of tocopheryl acetate as an isoform of vitamin E. The results of the same study also showed the potential of Brazilian spinach extract as a stimulant for lymphocyte growth in mice. Brazilian spinach is also known to contain iron and various vitamins such as vitamins A and C which function to overcome anemia (Limeranto, 2022). The presence of various vitamins and minerals in Brazilian spinach leaves has the potential to be used as functional food for human health, or as raw materials for drugs to overcome symptoms of infectious diseases that may arise. The presence of vitamin E in Brazilian spinach leaves can be used as an active ingredient for the formulation of cream preparations to treat wounds on the skin.

RESEARCH METHODS

Time and Place

The research was conducted at the Biotechnology Laboratory of Universitas Kristen Duta Wacana, Yogyakarta. The main ingredient of Brazilian spinach leaves used in this research is Brazilian spinach harvested from Ratri Garden, Mlati, Sleman, Yogyakarta and Gemah Ripah Garden, Bausasran, Yogyakarta in June - October 2023.

Tools and Materials

Some of the tools used in this research are glass jars, evaporators, and ovens to make ethanol extracts of Brazilian spinach leaves—tools for phytochemical tests drip pipettes, measuring pipettes, test tubes, funnels, and filter paper. As for the in vivo test, the materials used are aluminum spoons and bunsen to burn mice, cages, and food and drink containers for mice maintenance.

This study uses the basic ingredients of brazilian spinach leaves and 96% ethanol as the main ingredient for making ethanol extract of brazilian spinach leaves. Other materials used are cetyl alcohol, glycerin, triethanolamine (TEA), stearic acid, methyl paraben, propylparaben, and distilled water as ingredients for making ointment from ethanol extract of brazilian spinach leaves. The materials used for the qualitative test of phytochemical content of ethanol extract of brazilian spinach leaves are distilled water, Wagner's reagent, Mayer's reagent, concentrated HCl, Mg powder, FeCl_3 1%, ethanol 96%, anhydrous acetate, and concentrated H_2SO_4 . Materials for the in vivo test were mice, mice feed, and wood shavings, hair loss ointment to remove mice hair, Bioplacenton gel as a positive control and ointment of ethanol extract of brazilian spinach leaves.

Preparation of Ethanol Extract of Brazilian Spinach Leaf

The first stage in this research is the manufacture of Brazilian spinach extract as the main component in the manufacture of ointment of ethanol extract of Brazilian spinach leaves. The preparation of ethanol extract of Brazilian spinach leaves was carried out by the method used in the research previously conducted by Sipayung *et al.* (2023), which uses Brazilian spinach leaves that have been sorted then dried and mashed so that they become Brazilian spinach flour. This flour will then be soaked in 96% ethanol as a solvent or commonly referred to as the maceration extraction method. The maceration method is carried out repeatedly up to two times for 3 days. The ethanol extract of brazilian spinach leaves is then evaporated to separate the solvent from the extract that will later be used, after which it is put into the oven at 40 ° C until the extract thickens.

Phytochemical Test of Ethanol Extract of Brazilian Spinach Leaf

In this study, qualitative tests were carried out on the phytochemical content of ethanol extract of Brazilian spinach leaves. The first test carried out was the alkaloid test using the method previously carried out by Harbone (1987), the positive final result containing alkaloids was indicated by the formation of a precipitate at the bottom of the test tube after the ethanol extract of 0.2 grams of Brazilian spinach leaves was dissolved with 6 ml of distilled water, filtered and given a drop of Weagner reagent or given a drop of Mayer reagent. Second, the flavonoid content test uses the method performed by Harbone (1987), the final result of the ethanol extract of Brazilian spinach leaves will show a change in color to orange red if the results are positive after 0.2 grams of ethanol extract of Brazilian spinach leaves is dissolved with 4 ml of distilled water and filtered, then added and homogenized with 3 drops of concentrated HCl and 0.1 gram of Mg. Third, the tannin test was carried out using the method previously carried out by Hasibuan *et al.* (2022), the results of the ethanol extract of Brazilian spinach leaves were positive for tannins when the result was a change in the color of the extract sample to blue-black after 0.2 grams of Brazilian spinach ethanol extract was dissolved with 10 ml of distilled water and added with 3 drops of FeCl_3 1%. Fourth, the saponin test was carried out using a method that had been carried out in the research of Triwahyono & Hidajati (2020). Positive results for the presence of saponin content in the ethanol

extract of brazilian spinach leaves were indicated by the presence of foam at the top of the brazilian spinach leaf ethanol extract solution after heating and shaking by hand. Finally, steroid and terpenoid tests were carried out using the method performed by Harbone (1987). Positive results of steroid content in ethanol extracts of Brazilian spinach leaves will be indicated by changes in the color of the extract to blue green, while if it is positive for terpenoids, a purplish red ring will appear in the center of the sample after 0.2 grams of the ethanol extract was dissolved with 15 ml of 96% ethanol and added with 3 drops of anhydrous acetate and 1 drop of concentrated H₂SO₄, then homogenized.

Preparation of Brazilian Spinach Leaf Ethanol Extract Ointment

The stage of making ointment of ethanol extract of Brazilian spinach leaves was carried out using several ingredients and steps. The ingredients needed included cetyl alcohol, glycerin, triethanolamine (TEA), stearic acid, methyl paraben, propyl paraben, and distilled water. These ingredients are the basic ingredients of the ointment, which in the manufacturing process is carried out with the principle of mixing the water phase and the oil phase, so that these ingredients can be further grouped into water phase and oil phase basic ingredients. To be able to make the water phase, the ingredients needed are glycerin, triethanolamine (TEA), methyl paraben, and distilled water. Then, to be able to make the oil phase, the ingredients needed are cetyl alcohol, stearic acid, and propyl paraben. Each of the ingredients that make up the water phase and oil phase is heated at 55°C. After becoming homogeneous, it is allowed to stand until the temperature drops, then the two phases are mixed and stirred constantly until they reach room temperature. After it turns into a creamy form, it is separated into 4 for different treatment groups. After that, specifically for brazilian spinach ethanol extract ointment, 2%, 4%, and 8% extracts were added in different containers (Mudhana & Pujiastuti, 2021).

In Vivo Test of Brazilian Spinach Leaf Ethanol Extract Ointment

Federer's formula :

$$(n-1)(t-1) \geq 15$$

$$(n-1)(5-1) \geq 15$$

$$4n-4 \geq 15$$

$$4n \geq 19$$

$$n \geq 4,75$$

n= number of subjects per group

t= number of groups

The in vivo burn wound healing test was conducted using male BALB/c mice, totaling 20 mice grouped into 5 groups of 4 mice each. The treatment groups include:

Negative Control (KN) : Base cream ointment

Positive Control (KP) : Treatment of mice with burn wounds with Bioplacenton gel.

Treatment 1 (2%) : Ointment with 2% ethanol extract of Brazilian spinach leaves

Treatment 2 (4%) : Ointment with 4% ethanol extract of Brazilian spinach leaves

Treatment 3 (8%) : Ointment with 8% ethanol extract of brazilian amaranth leaves

Prior to in vivo testing, mice were acclimatized in a laboratory environment at room temperature for approximately 7 days. Feeding and drinking are done *ad libitum*. Then, lighting is given for 12 hours. Each group of mice is placed in a different cage according to the treatment group which aims to facilitate during the study. The study starts from the stage of making burn on the dorsal or back skin of mice to the stage of giving treatment and observation. The stage of making burn in mice begins with removing hair on the dorsal or back of the mice and applying *depilatory cream* to remove hair residues. After that, burn are made by attaching a metal plate or the tip of a heated metal spatula to the dorsal skin of mice that have been removed. To ensure that the dorsal skin of the mice was burned, the hot plate was applied for approximately 30 seconds. Then, the results were compared with normal mouse skin.

After making burn wounds on the dorsal part of the mice, the study continued with the treatment according to the group, which included: Negative Control (KN), Positive Control (KP), treatment 1, treatment 2, and treatment 3. During the treatment, the group of mice was observed for the level of healing from burn, with 2 different parameters, namely: burn *scoring* and burn surface area *scoring*. Each parameter was measured by giving a score ranging from 0 to 3, depending on the symptoms seen on the dorsal part of the mice. A score of 0 indicates the absence of burn symptoms on the dorsal part of the mice or the burn has healed and a score of 1 indicates there's still a little amount of dried out burn wound, redness, but there's no visible blisters. Meanwhile, if the burn were scored as 2-3 then, these burn may still be superficial but are more intense, involved a deeper portion of the epidermis and caused more inflammation (Johns Hopkins Medicine). Observation of the degree of healing of burn on the dorsal part of the mice was carried out for 7 days.

Data Analysis


Data that has been obtained in the form of burn *scoring* data and burn surface area *scoring*, quantitative data analysis is carried out to test the truth of the research hypothesis. Quantitative analysis was carried out using SPSS Statistics 25 *software*. Analysis was carried out with Non-Parametric Statistics with the KRUSKAL-WALLIS test. The confidence level was 95%.





RESULTS AND DISCUSSION

Phytochemical Screening Results of Brazilian Spinach Leaf Extracts

The results of phytochemical screening of ethanol extract of Brazilian spinach leaves showed that ethanol extract of Brazilian spinach leaves was positive for alkaloids, flavonoids, tannins, saponins and steroids. More details, the results can be seen in **Table 1**.

Table 1. Results of phytochemical examination on leaf of Brazilian Spinach

Test	Brazilian Spinach Leaf Extract Yield	Description
Alkaloid Test		
Weagner's reagent	+	
Meyer's reagent	+	

		Weagner's reagent: formation of a brown precipitate Mayer's reagent: formation of white or yellow precipitate
Flavonoid Test	+	 sample color became orange-red
Tannin Test	+	 Sample color turns blue- black
Saponin Test	+	 foam formed at the top of the sample
Terpenoid Test	-	 color change in sample and a red ring appears in the center of the sample.
Steroid Test	+	

Notes: (+) Phytochemicals detected, (-) No phytochemicals detected.

The results of *screening the* phytochemical content of ethanol extracts of brazilian spinach leaves if it is in accordance with the results of research conducted by Aryasa *et al.* (2024) and Limeranto (2022) which state that the phytochemical content of both the ethanol extract of spinach leaves and fresh Brazilian spinach leaves has phytochemical content in the form of alkaloids, flavonoids, saponins, tannins, and steroids. Each phytochemical content in Brazilian spinach has different benefits, therefore phytochemical screening was carried out in this study. One of the benefits of ethanol extract of brazilian spinach leaves that has been done by Wuni *et al.* (2022) is

the increase in the immune system of mice shown by an increase in the number of lymphocytes in the blood.

In Vivo Test Results

Table 2: Average Burn Score Between Brazilian Spinach Leaf Extract Ointment Treatments During 7 Days of Observation.

Treatment Group	Day 1	Day 2	Day 3	Day 4	Day 5	Day 6	Day 7
KN	3.00	3.00	2.00	2.00	2.00	2.00	2.00
KP	3.00	2.00	2.00	2.00	1.50	1.00	1.00
Treatment 1	3.00	3.00	2.00	2.00	1.50	1.25	1.00
Treatment 2	3.00	2.00	2.00	1.75	1.75	1.75	1.75
Treatment 3	3.00	3.00	3.00	3.00	2.00	2.00	2.00

Table 3. Average Burn Surface Area Score Between Brazilian Spinach Leaf Extract Ointment Treatments During 7 Days of Observation.

Treatment Group	Day 1	Day 2	Day 3	Day 4	Day 5	Day 6	Day 7
KN	3.00	3.00	3.00	3.00	3.00	3.00	3.00
KP	3.00	2.00	2.00	2.00	1.00	1.00	1.00
Treatment 1	3.00	2.00	2.00	2.00	1.50	1.00	1.00
Treatment 2	3.00	3.00	3.00	2.00	2.00	2.00	2.00
Treatment 3	3.00	3.00	3.00	3.00	3.00	3.00	3.00


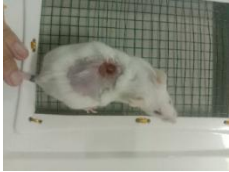

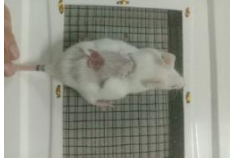

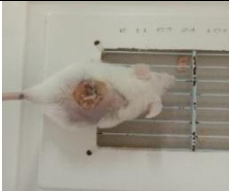




Based on **Table 2.** Average Burn *Scoring* for 7 Days, the healing process of burn on the dorsal skin of mice occurs for 7 days. The occurrence of the healing process is indicated by a decrease in the value or score of the burn wound formed, ranging from *scoring* 3 for severe conditions, *scoring* 2 for moderate conditions, *scoring* 1 for mild conditions, and *scoring* 0 for normal dorsal skin. Of the five treatment groups, each consisting of 4 mice as repetition, the average healing process occurs when entering day 3. It can be observed in **Table 2**, that the average *scoring* value on the first day was 3, then decreased to 2. Meanwhile, for the Positive Control and Treatment 2 groups, the healing process began to occur when entering day 2. The healing process still continues to occur. Then, on days 5 and 6, especially in the Positive Control and Treatment 1 groups, there was a decrease in the average value of *scoring* from 2 to 1. This decrease also occurred in Treatment 2 groups, especially mice repetition 4. However, until the last day of observation (day 7), all observation groups had not reached a *scoring* value of 0, which assumed that the healing process had taken place optimally.

Based on **Table 3.** Average *Scoring of Burn Surface Area* for 7 Days, shows that the burn healing process can also be indicated by a reduction in the surface area of the burned skin. Surface area measurements on the dorsal skin were also observed using a *scoring* system from 0-3, where *scoring* 3 indicates a severe condition with a fairly large size, *scoring* 2 indicates a moderate

condition, and *scoring* 1 indicates a mild condition with a small size, and *scoring* 0 represents normal skin. Of the five treatment groups, the average healing process occurred when entering day 2 to day 4. Although some other treatment groups did not show the healing process until day 7 which was the last day of observation. Groups that experienced a decrease in *scoring* on the surface area of the burn area were the Positive Control, Treatment 1, and Treatment 2 groups. In the Positive Control and Treatment 1 groups, the process of reducing the burn surface area also still occurred when entering day 5. The results obtained in this parameter also showed the same results as the Burn *Scoring* parameter, which on day 7 still did not show the healing process that took place optimally.

Based on the data obtained for 7 days, the data were analyzed by Non-Parametric statistical methods using the Kruskal-Wallis test on IBM SPSS Statistics 25 software. Data analysis was carried out with the aim of knowing the treatment group for ointment with ethanol extract of Brazilian spinach leaves (*Alternanthera sissoo*) which had the most optimal results, compared to the Negative Control and Positive Control groups.

Table 4. Differences of Each Treatment Mice Group Before and After Treatment.

Treatment	KN	KP	Treatment 1	Treatment 2	Treatment 3
Before					
After					

The surface area of burn in each treatment group before and after treatment appeared to be the same. Therefore, statistical analysis is needed.

The results of the Non-Parametric statistical analysis using the Kruskal-Wallis test and followed by the Dunn's Post Hoc test with a confidence level of 95% on the parameter of burn wound *scoring* for 7 days showed that for 2 days of treatment using ointment with 4% ethanol extract of Brazilian spinach leaves was the most optimal result, because the Sig. value against the Positive Control group was more than 0.05, so there was no significant difference. Meanwhile, the Sig. value against the Negative Control is less than 0.05, so there is a significant difference. When entering the 6th and 7th days, the treatment that showed the most optimal results was treatment group 1 with 2% ethanol extract of Brazilian spinach leaves. Then, in the parameter of *scoring the* burn surface area for 7 days, it shows that during the 7 days of treatment using ointment with 2% ethanol extract of brazilian amaranth leaves (Treatment group 1) is the most optimal result, compared to 4% ethanol extract of brazilian amaranth leaves (Treatment group 2) and 8%

(Treatment group 3). This conclusion is based on the Significance value, where the most optimal group must not be significantly different from the Healthy Control group (Sig. >0.05) and significantly different from the Negative Control group (Sig. <0.05). The reason for using the Non-Parametric statistical analysis test is because the data of the burn *scoring* parameter and *the scoring of the burn surface area* for 7 days did not meet the normality test and the homogeneity test.

The burn wound healing stage consists of several stages or phases, including: inflammation, proliferation, and remodeling (Arif, 2017 in Zakaria *et al.*, 2021). However, based on research by Price *et al.* (2021), the stages of burn wound healing consist of 4 stages, which include: hemostasis, inflammation, proliferation, and remodeling. The hemostasis phase occurs in the process of inhibiting bleeding by means of platelet aggregation. In addition, the wound healing process also occurs. The second stage is the inflammatory phase, where edema formation and inflammatory mediators occur, for 24 hours. The third stage is the proliferation phase, where collagen production occurs to help hold the burn wound together. This third stage can last for several days. The remodeling phase involves collagen rearrangement and collagen degradation. This stage can last for several months. By knowing the duration of burn wound healing from previous studies, it can be seen that the observation process during the treatment that lasted for 7 days was not the entire burn wound healing process of all treatment groups. Thus, of the two parameters observed in this study, none of the groups showed maximum burn wound healing (*scoring* value 0). To achieve a healing process that takes place maximally, up to a *scoring* value of 0 and there are no physical symptoms of burn on the dorsal skin of mice, the study can be carried out by adding the duration of treatment and observation.

The speed or slowness of the burn wound healing process can also be influenced by the presence or absence of infection symptoms in the area around the burn wound. Infection occurs due to the growth of bacteria or microorganisms that are difficult to prevent. Bacteria can grow on dead skin, because the area cannot be reached by capillaries (Kurnianto *et al.*, 2017 in Zakaria *et al.*, 2021). In addition to the death of tissue that allows the development of microorganisms, the presence of burn can also cause damage or dysfunction of the skin *barrier* and disrupt the cellular and humoral immunity system, so that the infection prevention process will be constrained. In addition, biofilm formation is also a factor that exacerbates infection (Stoodley *et al.*, 2002 in Mahdani *et al.*, 2022). This can occur because the mechanism of action of biofilm is to inhibit the effectiveness of antimicrobials given to inhibit the activity of microorganisms around the burn area (Edwards & Harding, 2004 in Mahdani *et al.*, 2022). Based on data from previous research through a systematic review conducted by Azzopardi *et al.* (2014), the types of bacteria found in burn infection cases are gram-negative types. The same thing was also found in the research of Mahdani *et al.* (2022). In burn patients who experienced infection, gram-negative bacteria were found as much as 62.5%, while gram-positive bacteria were 37.5%. The types of gram-negative bacteria include: *Acinetobacter baumannii*, *Pseudomonas aeruginosa*, and *Klebsiella pneumoniae*. Then, the types of gram-positive bacteria include: *Staphylococcus aureus* and *Staphylococcus hominis*. Based on research by Samiyah *et al.* (2022), the dominant types of bacteria that cause infection in burn cases suffered by patients at Dr. Soetomo Surabaya Hospital include:

Pseudomonas aeruginosa (16.7%), *Staphylococcus haemolyticus* (23.8%), and *Acinetobacter baumannii* (31%).

In the implementation of this study, the Positive Control group was treated using Bioplacenton® gel. This is in accordance with research conducted by Thomas *et al.* (2023), by comparing the use of bromelain enzyme as an alternative burn medicine and compared with Bioplacenton® gel products. Bioplacenton® gel is a type of drug with a dosage form in the form of a gel. Bioplacenton® gel products are often used as a medicine for burn and other wounds with symptoms of infection. The reason for using Bioplacenton is because Bioplacenton® gel has active ingredients in the form of *Placenta Extract* 10% and *Neomycin Sulfate* 0.5%. *Placenta Extract* has a role to accelerate the formation of new tissue, so that wounds can heal quickly. Meanwhile, *Neomycin Sulfate* has a role for antibiotics, thus inhibiting the growth of bacteria, especially gram-negative bacteria that can cause infection (Ginting *et al.*, 2021; Thomas *et al.*, 2023).

The results of the treatment group using brazilian spinach leaf extract ointment gave positive results on mice burn characterized by reducing the area of the burn area and decreasing the scoring of burn wounds. These results were obtained due to the content of vitamin E and phytochemical compounds such as alkaloids, flavonoids, steroids, terpenoids, tannins, and saponins. In brazilian spinach extract. Vitamin E is a type of fat-soluble vitamin. Vitamin E is composed of tocopherol and tocotrienol compound groups. Vitamin E plays a major role as an antioxidant in body tissues that can counteract free radicals that cause inflammation in body tissue. Vitamin E also modifies the connective tissue growth factor (CTGF) 17 gene and accelerates collagen formation to accelerate wound healing that occurs (Hobson, 2014; Thompson et al, 2022). The study by Wuni et al. (2022) showed that phytochemical compounds of alkaloids, flavonoids, and tannins can enhance the immune system, as seen from the increase in the number of lymphocytes. The steroid and saponin compounds have antimicrobial activity against bacteria and viruses.

CONCLUSION

The results of the phytochemical screening test on the ethanol extract of brazilian spinach leaves, showed that using maceration and 96% ethanol solvent can extract several phytochemical compounds, such as alkaloids, flavonoids, tannins, saponins, and steroids. Then, based on the results of the research that has been carried out by comparing the ointment of brazilian spinach leaf extract (concentrations of 2%, 4%, and 8%), shows that the treatment with a concentration of 4% is the most optimal treatment. This was shown after analysis using Non-Parametric statistical tests. Overall, the application of ointment with brazilian spinach leaf extract can reduce burn symptoms with parameters such as burn *scoring* and burn surface area *scoring* with a period of 7 days.

ACKNOWLEDGMENTS

Thanks to the National Achievement Center (Pusprenas) as the organizing institution of the Indonesian Student Research Olympiad (OPSI) Year 2023. In addition, thanks to those who contributed to the course of the research until publication, the Principal of SMA Negeri 11 Yogyakarta who has given the opportunity to be able to represent SMA Negeri 11 Yogyakarta to conduct this research, the supervising teacher from SMA Negeri 11 Yogyakarta who has guided in determining the research topic and Universitas Kristen Duta Wacana who has given the

opportunity to conduct research at the Laboratory of the Faculty of Biotechnology, Universitas Kristen Duta Wacana so that this research can be completed.

REFERENCES

- Arif (2017). Pengaruh Madu Terhadap Luka Bakar (The Effects of Honey in Skin Burn). *Medical Professional Journal of Lampung* 7(5), Halaman 71-74.
- Azzopardi, E. A., Azzopardi, E., Camilleri, L., Villapalos, J., Boyce, D. E., Dziewulski, P., Dickson, W. A., Whitaker, I. S. (2014). Gram Negative Wound Infection in Hospitalised Adult Burn Patients - Systematic Review and Metanalysis. *PLoS ONE* 9(4), e95042. <https://doi.org/10.1371/journal.pone.0095042>.
- Edwards, R., & Harding, K. G. (2004). Bacteria and Wound Healing. *Current Opinion in Infectious Diseases* 17, Pages 91-96. <https://doi.org/10.1097/00001432-200404000-00004>.
- Ginting, S., Harnis, Zola E., Ilsanna, C., Meliala, L. (2020). Perbandingan Efek Penyembuhan Luka Bakar Antara Gel Ekstrak Etanol Daun Afrika (*Gymnanthemum amygdalinum* Del.) dengan Gel Ekstrak Etanol Daun Kelapa Sawit (*Elaeis guineensis* Jacq.) serta Kombinasinya pada Kelinci Tahun 2019. *Jurnal Penelitian Farmasi & Herbal*, Vol. 3, No. 1, Halaman 82-90. <http://ejournal.delihusada.ac.id/index.php/JPFH>.
- Harborne, J. B. Metode Fitokimia: Penuntun Cara Modern Menganalisis Tumbuhan, Diterjemahkan Oleh Kosasih Padmawinata Dan Iwang Soediro. Penerbit ITB, Bandung 1987.
- Hasanah, U., Irwan, Andi A., Malli, R. (2023). Tingkat Pengetahuan Tentang Penanganan Luka Bakar pada Tim Bantuan Medis. *FLORONA, Jurnal Ilmiah Kesehatan* Vol. 2, No. 2, Halaman 67-72. ISSN: 2829-3835 (Print), ISSN: 2829-3983 (Elektronik). <https://jurnal.arkainstitute.co.id/index.php/florona/index>
- Hasibuan, N.E., Aulia, A., Basri., & Apri, M. (2022). Skrining fitokimia ekstrak etanol daun Avicennia Marina dari kawasan Bandar Bakau Dumai. *Authentic Research of Global Fisheries Application Journal*. 4(2), 137-142.
- Johns Hopkins Medicine. "Burn and Wounds." *Johns Hopkins Medicine*, <https://www.hopkinsmedicine.org/health/conditions-and-diseases/burn>. Accessed 9 May 2025.
- Kurnianto, S., Kusnanto, dan Padoli. (2017). Penyembuhan Luka Bakar pada Tikus Putih dengan Menggunakan Ekstrak Daun Pegagan (*Centella asiatica*) 25% dan Ekstrak Daun Petai Cina (*Leucaena leucocephala*) 30%. *Jurnal Ilmiah Kesehatan* 10(2): 250-255.
- Limeranto, D.M. (2022). Pengaruh Ekstrak Bayam Brasil (*Alternanthera sissoo*) Terhadap Profil Hemoglobin, Hematokrit, dan Eritrosit Mencit (*Mus musculus*) yang Diinduksi Natrium Nitrit (NaNO_2). Skripsi. Fakultas Bioteknologi. Universitas Kristen Duta Wacana. Yogyakarta.
- Mahdani, W., Rizal, S., Amirsyah, M. (2022). Evaluasi Kejadian Infeksi pada Pasien Luka Bakar yang Dirawat Inap di RSUD dr. Zainoel Abidin. *Jurnal Ilmu Medis Rumah Sakit Umum dr. Zainoel Abidin*, Vol. 3, No. 2, Halaman 71-79. e-ISSN: 2721-7884. <https://doi.org/10.55572/jms.v3i2.69>.
- Mudhana, Aditya R. & Pujiastuti, A. (2021). Pengaruh Trietanolamin dan Asam Stearat Terhadap Mutu Fisik dan Stabilitas Mekanik Krim Sari Buah Tomat. *Indonesian Journal of Pharmacy and Natural Product*, Vol. 04, No. 02, Hal. 113-122. <http://jurnal.unw.ac.id/index.php/ijpnp>.
- Price, A., Grey, J. E., Patel, G. K., & Harding, K. G. (2021). *ABC of Wound Healing*. John Wiley

& Sons.

- Rahayuningsih, T. (2012). Penatalaksanaan Luka Bakar (Combustio). *PROFESI*, Volume 08, Halaman 1-13.
- Samiyah, Wardhani, Indrayuni L., Saputro, Iswinarno D. (2022). Hubungan Antara Infeksi dan Lama Perawatan Pasien Luka Bakar Berdasarkan Jenis Kuman di RSUD Dr. Soetomo Surabaya. *Jurnal Rekonstruksi dan Estetik*, Vol. 7, No. 1. <https://doi.org/10.20473/jre.v7i1.36369>.
- Saputra, D. (2023). Tinjauan Komprehensif tentang Luka Bakar: Klasifikasi, Komplikasi dan Penanganan. *Scientific Journal*, Vol. II, No. 5, Halaman 197-208. e-ISSN: 2810-0204. <http://journal.scientic.id/index.php/sciena/issue/view/12>
- Sipayung, D. A., Titiaryanti, N. M., & Astuti, Y. T. M. (2023). Pengaruh Konsentrasi dan Cara Aplikasi Eco Enzyme terhadap Pertumbuhan Bibit Kelapa Sawit di Pre Nursery. *Jurnal Agroforetech*, 1(1), 90–93. <https://jurnal.instiperjogja.ac.id/index.php/JOM/article/view/387>
- Stoodley, P., Sauer, K., Davies, D. G., & Costerton, K. J. (2002). Biofilms as Complex Differentiated Communities. *Annual Review of Microbiology*, 56: 187-209. <https://doi.org/10.1146/annurev.micro.56.012302.160705>.
- Syaiful, S., Majid, S., Abrar, Eva A., Amir, H. (2023). Pengaruh Pemberian Zinc Cream Epitel Terhadap Penyembuhan Luka Bakar Derajat III: Study Kasus. *Jurnal Ilmiah Permas: Jurnal Ilmiah STIKES Kendal*, Vol. 13, No. 1, Halaman 83-90. e-ISSN: 2549-8134; p-ISSN: 2089-0834. <http://journal.stikeskendal.ac.id/index.php/PSKM>
- Thedjakusuma, Fritzky W., Nahusuly, F., Arius, Y. (2022). Perbandingan Tingkat Penyembuhan Luka Bakar Derajat II B (*Deep Dermal*) pada Fase Proliferasi yang Ditinjau dengan Pemberian Larutan Feracrylum 1%, Tulle, dan Silver Sulfadiazine pada Mencit *Mus musculus*. *Jurnal Kedokteran Mulawarman*, Vol. 9 (3), Halaman 122-131.
- Thomas, Nur A., Taupik, M., Djuwarno, Endah N., Papeo, Ramadani P., Djunaidi, Nabila N. (2023). Uji Penyembuhan Luka Bakar Gel Enzim Bromelin Menggunakan Carbopol 940 Secara In Vivo. *Journal Syifa Sciences and Clinical Research*, Vol. 5, No. 2, Halaman 232-244.
- Triwahyuono, D. & Hidajati, N., 2020. Uji Fitokimia Ekstrak Etanol Kulit Batang Mahoni (*Swietenia mahagoni* Jacq). *Unesa Journal of Chemistry*, 9(1), 54-57. <https://doi.org/10.37311/jsscr.v5i2.20364>.
- Wuni, P.M., Madyaningrana, K., Prakasita, V.C. (2022). The Effect of Brazilian Spinach (*Alternanthera sissoo hort*) Leaf Extract on Lymphocyte Count and Organ Index of Male Mice. *Metamorfosa: Journal of Biological Sciences*, 9(2), 397-406. <https://doi.org/10.24843/metamorfosa.2022.v09.i02.p19>.
- Zakaria, A., Erviani, Andi E., Soekendarsi, E. (2021). Uji Potensi Getah Pepaya (*Carica papaya*) Terhadap Kecepatan Penyembuhan Luka Bakar Kulit Tikus *Rattus novergicus*. *Jurnal Ilmu Alam dan Lingkungan* 12(2), Halaman 40-46. <https://journal.unhas.ac.id/index.php/jai2>.